

Percutaneous valvuloplasty

JC Ragg

Introduction

The main feature of venous insufficiency is reflux, meaning that closure of one or several vein valves is not achieved during regular body movements. In late stages, the valve cusps are badly damaged or totally gone because of chronic inflammation; thus, surgical removal or endoluminal closure are the best options of treatment. However, in early stages, a valve may leak while the cusps are fully preserved and mobile. In this case, reduction of vein diameter could result in functional restoration. A first attempt to restore venous valves in case of insufficiency is extraluminal valvuloplasty; also called extraluminal stenting. A surgical tissue patch made from Dacron or polyurethane is wrapped around the surgically prepared vein and fixed with sutures like a coat. Thus, the diameter is reduced and the valves may work again. There are more than 15 years of positive functional experience with this method,¹⁻³ in spite of rather insufficient case selection due to former ultrasound limitations. However, the surgical approach usually requires general anaesthesia, it is even more extended than crossectomy and the result cannot be adjusted later on. The patch will be a lasting foreign body. Serious complications such as wound infection are rare, but may happen. Therefore, open surgery seems not to be the best option for the aimed treatment of early stages, in potentially younger people. Endoscopically guided procedures of valvuloplasty⁴ have recognised that the procedure should be less invasive, but the technique was too complex to proceed to routine.

Percutaneous valvuloplasty

The idea to shape veins or to reduce their diameter by injectable fluids is known and practised for more than 15 years when applying saline solutions in the perivenous space prior to thermal treatments of veins, called tumescent anaesthesia, based on a well-known supportive mode for liposuction.⁵ In experienced vein centres, tumescent anaesthesia is performed strictly under ultrasound guidance. A cannula is advanced to the perivenous space in local anaesthesia and then fluid is injected in a way distributing it around the vein until sufficient reduction of vein diameter is accomplished. The effect of saline fluids is lost within days by resorption. The experience in precise ultrasound-guided vein shaping by perivenous fluids led our working group to the invention of percutaneous valvuloplasty in 2012; first choosing native hyaluronan gel of low viscosity to achieve proof of principle, and afterwards changing to more solid cross-linked hyaluronan products to obtain more durable results (Figures 1 and 2).⁶ Among many initial questions, one was aimed at the particle size to use—should it offer a maximum compression effect with large particles? Or should it be precise first of all and, thus, consist of small

particles? In this chapter, we present a comparison of two evaluated substances with a two-year follow-up.

Two initial studies comparing different hyaluronan products

Cases with proximal greater saphenous vein valve incompetence but preserved and mobile valve structures, according to 8–16MHz ultrasound analysis were included. In series A, 23 patients (15 female, eight male; 38–67 years, diameter range 7–11.5mm, mean 8.6mm) underwent percutaneous valvuloplasty using a hyaluronan gel consisting of large particles (>1mm; Macrolane, Galderma). In series B a smooth hyaluronan gel (particle diameter <0.2mm; Princess Volume, Croma/Star) was chosen for 18 patients (12 female, six male; 34–69 years, greater saphenous vein diameter 7–11.8mm, mean 8.9mm). Injections were performed under sterile conditions with local anaesthesia from one single access using a patented safety cannula, consisting of a sharp tip to penetrate skin, fasciae and ligaments and, by turn of the handle, changed to a blunt tip to navigate in areas close to veins, to avoid incidental vessel puncture or intravascular injection. All procedures were performed strictly and continuously under ultrasound monitoring. Patient position was upright on a tilt table for marking, intermediate and final result control, and supine (0–20 degrees) during puncture and injections. Injections were carried out air-free to avoid disturbance of ultrasound signals. Treatment was terminated when the vein diameter was reduced to estimated normal or in case of proven elimination of reflux. Follow-up examinations with ultrasound were performed after three, six, 12, 18 and 24 months. Supplementary injections of hyaluronan were allowed.

Results

Orthograde flow could be established in 22/23 cases of series A (95.6%) and 18/18 cases of series B (100%) in one session (A: 18, B: 17) or two sessions (A: 4, B: 1) (Figure 3). Gel volumina were 12–35ml (mean 19.4ml, series A) vs. 4–9ml (mean 6.9 ml, series B). After an initial learning curve, injections became more precise and effective. In two cases, a local overload of hyaluronan was successfully aspirated. There were no adverse reactions, in particular no sensation of local swelling or pressure, not even in cases with large volumina of hyaluronan. At

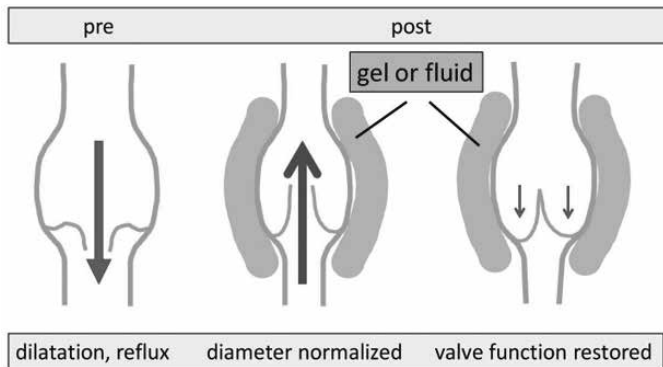


Figure 1: Principle of percutaneous valvuloplasty.

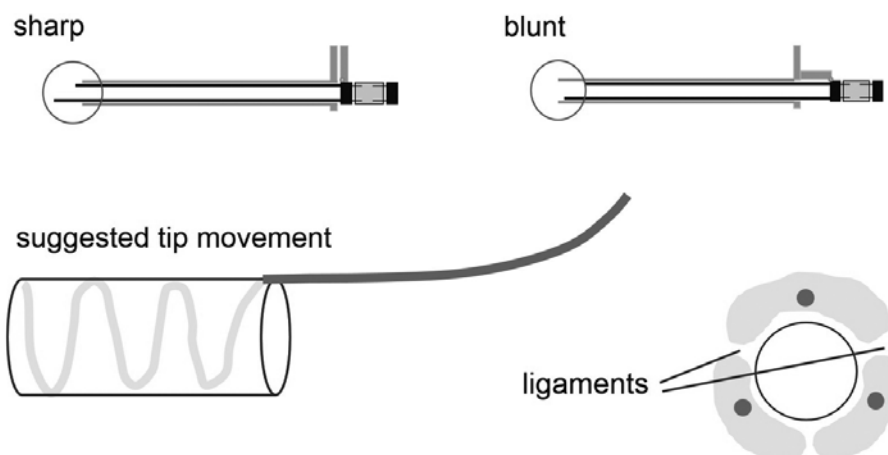


Figure 2: Flexible safety canula for percutaneous valvuloplasty and suggested way of injection.

one year follow-up, orthograde flow was present in 15/22 cases (68.2%, series A) *vs.* 14/18 cases (78.6%, series B). Cases with recurrent reflux (A: n=7, B: n=4) successfully received supplementary hyaluronan injections of the substance initially chosen, volumes were 2–6ml. After two years, orthograde flow was found in 14/22 cases (63.6%, series A) *vs.* 11/18 cases (61.1%, series B). Again, supplementary injections were performed with haemodynamic success in all cases but one (suspected valve damage, converted to thermal closure). A number of cases (A: n=7, B: n=4) had orthograde flow after two years without any supplementary injection. Both substances decreased with time, but the time curve was not clear as the depictability of hyaluronan got lost between months eight and 18 while a certain volume effect, according to the vein diameter, still existed.

Discussion

Hyaluronan has been proven in large numbers of cases worldwide to reside within the human body with excellent biocompatibility, in particular after the introduction of non-animal based hyaluronic fillers.⁷ The rate of adverse reactions is very low. Serious mistakes like intravascular injections⁸ can be avoided by proper tools and technique. Macrolane is usually chosen for reasonable aesthetic large volume corrections, with drawbacks by interference of mamma augmentation with the early diagnosis of breast cancer. Other volume-increasing indications are still practised.⁹ Princess is a smooth aesthetic product, among others, designed for the treatment of facial wrinkles.¹⁰ It is obvious that small particles allow smaller tools and a more precise delivery,¹¹ in this study, as indicated by a much smaller gel consumption. Nevertheless, treatments in series B were more expensive as the costs per millilitre were approximately four-fold compared to Macrolane. Long-term results were not significantly different. So far, both types of hyaluronan are eligible for the (study-related) purpose of valvuloplasty, unless a manufacturer proceeds to provide a novel product with intermediate particle size and the product is subsequently improved for commercial use.

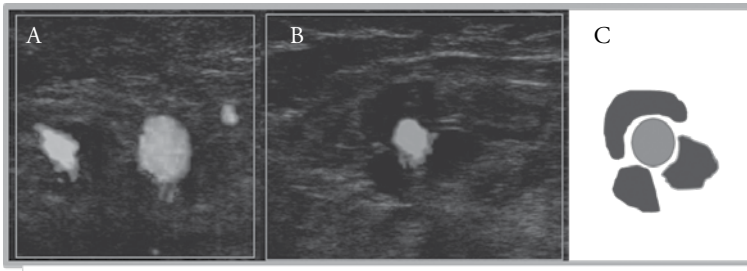


Figure 3: Cross-sectional ultrasound view of (A) dilated, refluxive vein, (B) after hyaluronan injection, (C) scheme. The horizontal gaps indicate the saphenous ligaments

The quality of valvuloplasty depends not so much on the technique, which is rather simple, but on inclusion criteria. Many valves considered “preserved and mobile” will show cellular aggregates, rough parts of the surface, increased thickness or even small structural defects when examined with the newest high-resolution ultrasound systems.

Besides the intention of functional restoration of vein valves (valvuloplasty), there might be a reason to consider venoplasty to achieve haemodynamic improvements in dilated zones when valves are missing or destroyed, potentially applicable to a much larger number of cases. However, a scientific basis is not yet provided.

The effects of valvuloplasty or veinoplasty or should last for years until the vein has gained stable healthy haemodynamics. This aim may be supported by further measures to fight stasis and congestion, like physical training, wearing of compression stockings, or medication. It is a fiction to eliminate venous insufficiency, since there are pathomechanisms (e.g. congenital valve defects, inflammation, degeneration) apart from simple dilatation, but there seems to be a relatively simple way to at least delay the onset of symptoms and varices.

Conclusions

Percutaneous valvuloplasty is the first minimally invasive method to eliminate venous reflux while fully preserving the target vein. It is as feasible as with large-particle hyaluronan as with smoother gels. Small particle gels may be placed more precisely but are much more expensive when designed to be long lasting. Efforts are now focused on encouraging manufacturers to provide a definite substance for approval.

Summary

- It may be assumed that many cases of venous insufficiency pass a stage characterised by reflux in one dilated valve zone, but still fully preserved and mobile vein cusps. This stage may exist for years, but is seldom recognised as it is usually long before symptoms or varicosities appear.
- In this stage, valvuloplasty is an effective principle to achieve functional restoration, proven by surgical wrapping.
- Percutaneous valvuloplasty by perivenous injection of biocompatible gels like hyaluronan is the first non-surgical modality for long-term vein diameter reduction. It can be exactly adjusted to the required diameter. Supplementary injections, if necessary, are easy to perform.

References

1. Lane RJ, Cuzzilla ML, Coroneos JC *et al.* Recurrence rates following external valvular stenting of the saphenofemoral junction: a comparison with simultaneous contralateral stripping of the great saphenous vein. *Eur J Vasc Endovasc Surg* 2007; **34** (5): 595–603.
2. Belcaro G, Agus G, Errichi BM *et al.* Gore external valve support for superficial saphenous vein incompetence: a 10-year, follow-up registry. *Panminerva Med* 2011; **53** (3 Suppl 1): 35–41.
3. Sarac A, Jahollari A, Talay S *et al.* Long-term results of external valvuloplasty in adult patients with isolated great saphenous vein insufficiency. *Clin Interv Aging* 2014; **9**: 575–79.
4. Komai H, Juri M. Deep venous external valvuloplasty using a rigid angioscope. *Surg Today* 2010; **40**: 538–42.
5. Klein JA. The tumescent technique for liposuction surgery. *AM J Cosmetic Surg* 1987; **4**: 1124–32.
6. Ragg JC: A New Modality to Shape Enlarged Veins and Restore Valves by Perivenous Injection of Viscous Fluids. *J Am Coll Cardiol Intv* 2014; **7**: S33.
7. Ahn CS, Rao BK: The life cycles and biological end pathways of dermal fillers. *J Cosmet Dermatol* 2014; **13**(3): 212–23.
8. DeLorenzi C: Complications of injectable fillers, part 2: vascular complications. *Aesthet Surg J* 2014; **34** (4): 584–600.
9. Cerqua S, Angelucci F: Macrolane (large particle biphasic hyaluronic acid) filler injection for correction of defect contour after liposuction. *J Cosmet Laser Ther* 2013; **15** (4): 228–30.
10. Kopera D, Palatin M, Bartsch R *et al.* An open-label uncontrolled, multicenter study for the evaluation of the efficacy and safety of the dermal filler Princess VOLUME in the treatment of nasolabial folds. *Biomed Res Int* 2015;195328.
11. Kim YS, Choi JW, Park JK *et al.* Efficiency and durability of hyaluronic acid of different particle sizes as an injectable material for VF augmentation. *Acta Otolaryngol* 2015; **6**: 1–8.

